OPHTHALMOLOGY

BY:

PHLEGON

Anatomy and physiology of human eye.

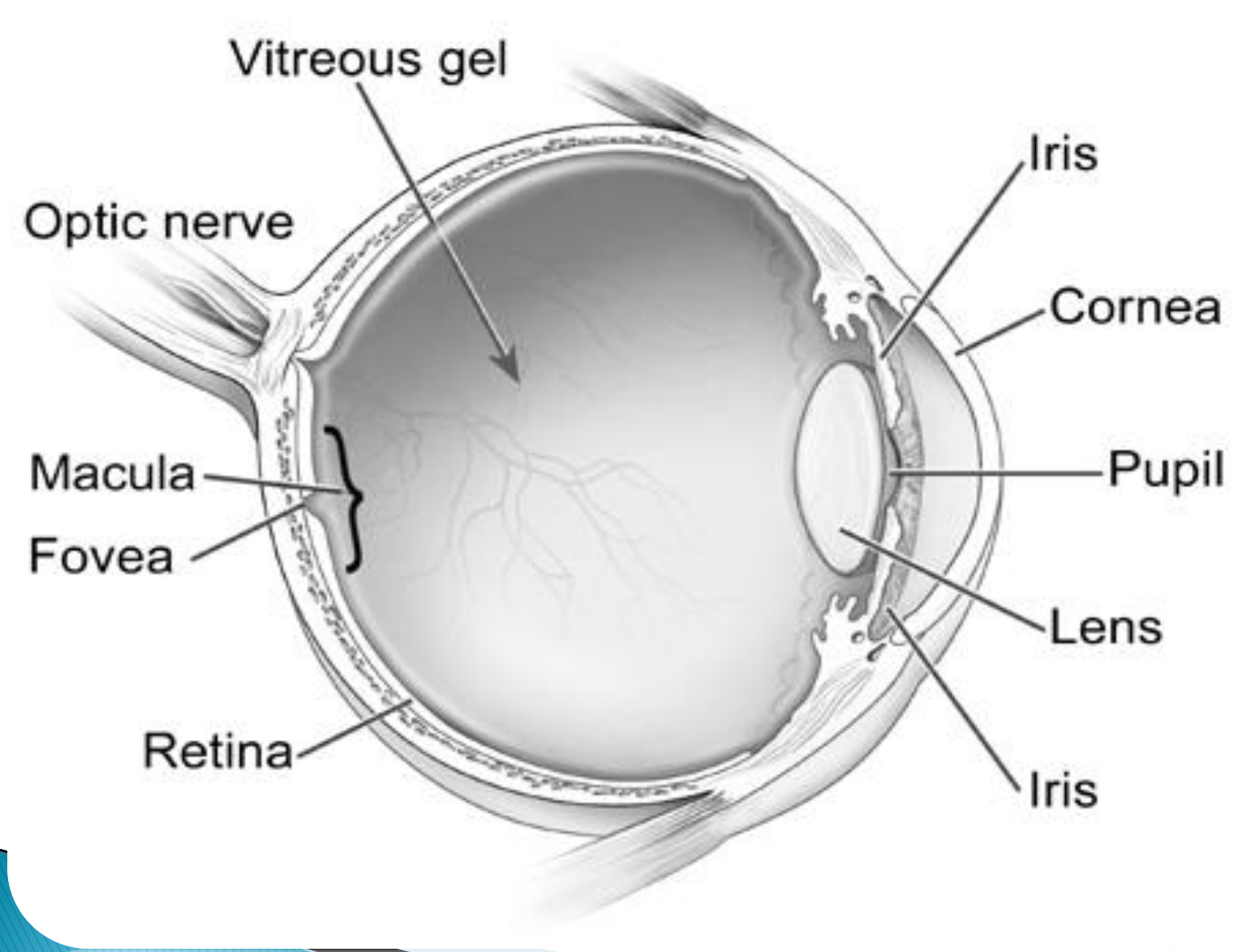

Eyebrows–protect eyeball from sweat, dust and other foreign bodies.

Eyelids –movable folds acting as curtains, preventing injuries. Meet at palpebral fissure(both eyelids meet). It contains sebaceous glands, sweat glands and accessory lacrimal glands all aligned with conjuctival material.

Conjunctiva–clear, delicate mucous membrane. it lines the eyelids and is highly vascularised. It protects the eye against infections. It also acts as a physical barrier, and produces mucin (goblet cells)which lubricates the eye ball.

Sclera-is a fibrous tissue of the eye(white),is tough and contains collagen fibres, and covers 5/6 of the eyeball. It protects inner structures maintains the shape of the eyeball. It also acts as a passage of blood vessels and nerves

Cornea-covers 1/6 of the eyeball. Its clear, transparent and has 5 layers.

Its functions include;

- protection of the eye as it's very sensitive.
- Refractive media of the light. and
- Prevents aqueous from coming out of the eye

Anterior chamber

Is just behind the cornea and its functions include;

- Refractive media
- Maintains shape and structure of the eyeball
- Bathes/nourishes the eyeball.

NB: inflow and outflow of aqueous humour maintains the eye pressure.

Production and flow of aqueous humour.

A.H is secreted by the epithelial cells of the ciliary body. it passes through suspensory ligaments into the posterior chamber, then flow through the pupil into the anterior chamber. From anterior chamber it drains through trabecular meshwork into the canal of schlemm (scleral venous sinus) then goes to the general circulation.

Iris–is the thin visible, contractile, and coloured part of the eye, with a central aperture known as the pupil. It divides the anterior segment of the eye into anterior and posterior chambers. It controls amount of light entering the eye and plays a role in accommodation.

Ciliary body–Is continuous with choroid(middle layer of eyeball). It suspends the lens which is important during accommodation, and produces aqueous.

Choroid–Is the soft brown part behind the eye. Is most vascularised, and nourishes the retina.

Lens–is the transparent, highly elastic biconvex body, that lies immediately behind the pupil/front of the vitreous body. Its thickness is controlled by ciliary muscle through the suspensory ligaments.

Its functions include:

- Refractive media
- Absorbs ultra violet rays
- Accommodation.

Retina–Innermost layer of eyeball where images are formed. It has macula, optic disk, rods and cones. It consists of 2 layers.

- ✓ Epithelial layer.
- ✓ Nervous layer
- It absorbs light.
- Stores and releases vitamin A.

Vitreous body–is transparent, jelly like media.

- It maintains the shape of eyeball and acts as refractive media.

Eye examination

Indications

- When a patient has complaints
- Post-operatively
- Routine schools
- Before instillation of drugs.

NB

Start examination from outwards to inwards

Things to check for;

Lid

- Ptosis-(dropping of the upper lid)check edema, congenital malformation, trauma etc.
- Proptosis-(protruding eye ball) discharge.
- Entropion(turning inside of the eyelid)
- Ectropion-(turning outward of the eyelid)

Conjunctiva

Redness of the eye(infection),hyperaemia, haemorrhage, laceration, growth, swollen, scaling or crusting.

Evert the upper eyelid-examine the upper part.-papillae'(allergies),tearing or blinking is noted, discharge etc.

Cornea

Abrasions, scars, foreign bodies and corneal ulcer. Use light (flourescein test).

Anterior chamber-

- blood (haephema)
- pus (hypopyon)
- extra cells-products of inflammation.

Iris-colour (brown, black, colourless).check whether it is adhering to the cornea or the lens,inflammed etc

Pupil- size, shape, position, reaction to light. through the pupil you'll be able to see the lens.(normal colour -colourless)

Visual acuity

- Is the acuteness or clearness of the central vision.

Indication

- Routine for eye patients.
- Where there is a complaint.

Requirements(trial frame)

- Tray with an occlude(block), E-chart/model, snellen chart. Stool, torch, cotton wool (discharges),mirror.

Procedure

- Room with 6metres,or 3metres with a mirror.
- Identify the patient, put the chart and find whether he/she can read.
- Explain the procedure(always start with the right eye-block left)
- Normal 6/6
- Wave the hand(hand movement)
- Shine a torch9 from all directions and ask pt to locate the direction of the light.
- Light off

Always record the findings.

Near vision (Rosenburn test)

- Near vision chart is used.
- Place at 14-16 inches from the eyes or arm length distance.
- Use the trial frame to occlude left eye while you assess the right eye.

Other special techniques

a) Tonometry–Use of tonometers for measuring eye pressure(mmHg).
b) Genioscopy –measuring the angle of the eye.
c) Binocular ophthalmoscope–for detailed of the eye. E.g the fundus of the eye.
d) Phoropter–a refractor with millions of lenses combination.
e) Colour sense (ishihara test).

1. BLEPHARITIS

- Acute or chronic inflammation of the eye margin lid. Usually bilateral.

It can be caused by:

- Bacterial Strept (normally chronic),staph. Etc
- Mechanical trauma e.g sunburn.
- Excessive lipid secretion (seborrhoic blephritis)
- Associated with poor hygiene, cosmetics-make ups, malnutrition etc.
- May also be caused by acne.

Clinical features:

- lid margin red swollen, swollen or ulcerated
- itchiness around the eye
- burning sensation and irritation discharge.
- Discharge from the eye.

Management:

- Proper hx taking-previous infection
- Take a swab for culture and sensitivity.
- Do proper eye examination and clean the lid with warm n.saline.
- Antibiotics ointment(T.E.O) tds*3days
- Systemic antibiotics-tetracycline caps.250mg tds*1/52
- Steroids are a times used.
- Health education on strict hygiene, nutrition, right non-irritant make-ups etc.
- If it persists or severe then removal of eyelashes is necessary (epilation), using epilation forceps.

Complications

- Conjunctivitis.
- Trichiasis-lashes turn in.
- Entropion-eye lid edges turn in.
- Ectropion-eye lid edges turn out.
- Corneal ulcer.

2. STYE(EXTERNAL HORDEOLUM)

- Inflammation of hair follicle of the eyelash or the small lubricating glands of the lid margin
- Abscess forms at points near eyelash.

Causes

- Bacterial S.aureus
- Associated with diabetic patients

Clinical features

- swelling eye lids, situated at eye lashes at the skin.
- Pain
- Tenderness
- Fever

Diagnosis

- Hx taking-acute illness(sudden onset)
- Eye examination

Management

- Antibiotics T.E.O 1% or gentamicin eye drops.
- Analgesics for pain
- Clean tds with warm N/S. The stye may open on its own and drain.
- epilation-removal of the eyelash to give way for the pus and then pad the eye for 24 hours.
- Health education on personal hygiene, avoidance of excessive cosmetic use.
- Surgery-I&D under L.A,if it persists.

Complication

- Conjunctivitis
- Recurrence on another site.

3. CONJUNCTIVITIS

- Inflammation of the conjuctiva.
- ✓ Fungal conjunctivitis
- ✓ Parasitic conjunctivitis
- ✓ Viral conjunctivitis
- ✓ Bacterial conjunctivitis
- ✓ Traumatic conjunctivitis.
- ✓ Allergic conjunctivitis

1. Bacterial conjunctivitis

Inflammation is caused by bacteria. E.g N.gonorrhoea, S.aureus, S.pneumoniae, H.influenzae.

Clinical features

- conjuctival redness(increase blood supply to the eye)
- sticky discharge especially in the morning(all bacterial accumulated)
- lid inflammation (swelling)
- foreign body sensation(gritty feeling)
- Photophobia.

Diagnosis

- Hx taking and eye examination
- swab- for culture and sensitivity.

Management

- Antibiotics-CAF, ciprofloxacin or T.E.O tds gentamicin tds for 1 week.
- Clean eye frequently with warm N/S.
- No eye padding as it increases the rate of infection
- Health educ to pts good on personal hygiene-face washing before going to bed, balanced diet with a lot of vit. A & B.
- Avoid direct light.
- Irrigation may be necessary.

Complication

- Corneal ulceration

2. Viral conjunctivitis

- Viral causes include adenovirus, herpes simplex, measles.

Clinical features

- red pale eye.
- Swollen conjunctiva.
- keratitis(inflammation of the cornea)
- in severe, bleeding from the conjuctival vessels- sub conjuctival bleeding.
- Photophobia.
- watery discharge.

Management

- Examination
- Swab-viral studies
- Antibiotics to prevent complications
- Antiviral e.g. acyclovir3%*10/7 eye drops. Oral dose 400mgs qid for 5days.

- **NB** don't overuse steroids as lowers immunity

3. Allergic conjunctivitis

- 60% suffer allergic-allergens

Types include:

- Hay fever-(seasonal)
- Eczema
- Glass especially contact lens.

Clinical features

- eye irritation /itching
- red eye papillae
- photophobia
- burning sensation
- watery discharge

Management

- Antihistamine,
- Small doses of steroids e.g. betamethasone
- Antibiotics.
- Avoid allergens
- Desensitization
- Dark glasses in cases of photophobia

Common allergens include

- Cold wind
- Pollen
- Animal fur perfumes etc

Complications

- Keratitis

Prevention

- advice eczema patients on tx.
- avoidance of trauma/sharp objects eg stones
- Use safety belts.

KERATITIS

- Is the inflammation of the cornea.

Causes

- Micro organisms e.g. bacteria, fungi, viruses.
- Contact lens wear
- Exposure due 2 poor lid closure(dryness of cornea) related to nerve palsy and exophthalmos.
- Diseases of the cornea and sclera
- Direct trauma like u.v. radiations
- Prolonged use of steroids
- Allergens

Clinical features

- foreign body sensation
- very painful
- photophobia
- Reduced/ blurring vision
- hypopion- pus in the anterior chamber.
- Excessive tearing /lacrimation.
- Red eyes.

Investigations

- Hx. And p. eye examination
- Scrapes of cornea(KOH) microscopy filaments(fungal)

Management

- Atropine which act as mydriatics
- Antifungal e.g. ketoconanole
- Antibiotics e.g. flucloxacilin
- Keratoplasty.

Complications

- Corneal ulceration
- Corneal perforation
- Corneal opacity
- Uveitis
- Glaucoma

Prevention

- Good care of contact lens
- Early treatment of eye conditions
- Prevent trauma
- avoid allergens
- avoid prolonged use of steroids
- infection prevention in equipments in hospitals

5. GLAUCOMA

- increased intraocular pressure is enough to cause damage to the eye structures.
- Normal IOP=12-20mmHg.
- Measured using **tonometer.**

Factors that maintain normal IOP

- Rate of formation of AH
- Rate of drainage of AH.
- Elasticity of cornea and sclera.

TYPES

a) closed angle glaucoma.(acute)
b) Open-angle glaucoma.(chronic)
c) Secondary glaucoma.
d) Congenital (Buphthalmos(ox-eye).

Pathophysiology

- The mech. of visual loss is ganglion cell atrophy. The optic nerve, the iris, and the ciliary body becomes atrophic.

NB in acute closed angle glaucoma, IOP may rise to(60-80), resulting in ischemia.

a) Acute closed angle glaucoma(primary angle closure)

- It may be due to closure drainage channel. Has sudden onset and may be uni/bilateral.
- blocked trabecular meshwork with a wide pupil.
- may occur in children.

Clinical features

- Sudden onset with severe eye pain.
- Blurring vision/loss of vision.
- Abdominal pain and vomiting(s/s like malaria)
- swollen lids, iris and conjunctiva.
- shallow A.C
- Pupil fixed and dilated.

Diagnosis

- History and physical examination of the eye.
- Investigations:

-visual acuity

-Tonometry (eye pressures).

-Gonioscopy (measure of the depth of the A.C)

Management

- Control pain-analgesics/admit and nurse the pt in a dark room.
- Give a pt a bowl for vomiting
- Cold compressions on the forehead

- Give diamox 500mgs stat to reduce production of aqueous humour(acetazolamide)
- Bedpan and urinals –elimination
- Give pilocarpine 4% to the affected eye and 2% to the unaffected eye.
- Beta blocker to lower production of aqueous.
- Mannitol i.v 20% in 500mls(i/output chart balance)
- Glycerol (liquid) p.o(take with juice)1-5mg/kg bwt-60mls STAT(adult)
- Iridectomy-hole is made using a laser bim.

(Specific pre/post operative care.)

b) Chronic open angle glaucoma

- Above 45 yrs both sexes occurring in a progressive nature (gradual).
- Uni/bilateral
- It can be inherited
- Cause is idiopathic but associated with age, diabetes and HTN.

Clinical features

- Asymptomatic initially, no pain, no irritation. The patient loses sight slowly.
- Then loss of visual fields.
- Cupping of optic disc due to direct pressure on the optic n. (fundoscopy).
- visual acuity
- Deep AC and the pressures are moderate.

Diagnosis

- Examination, hx taking,
- visual acuity-reduced visual fields
- Gonoscopy
- Tonometry
- Opthalmoscopy-cupped optic disc

Medical Management

- Use of drugs to control pressure is the treatment of choice.
- Maintain the patient with drugs like pilocarpine eye drop b.d (miotics) to reduce pressures by constricting the pupil.
- Beta blocker e.g. timolol to reduce aqueous production.
- Hypersmodics e.g. glycerol to reduce pressures.
- Prostaglandin to increase drainage of aqueous.

Surgical mnx

- prepare the pt once the pressures are controlled.
- Trabeculectomy- aqueous is made to drain through sclera. some trabecular meshwork are removed and a hole left to allow the flow.
- pre/post prep –just like other patients
- Done under local anaesthesia.
- **NB**:if not successful, laser trabeculoplasty is done.

Complications

- Over drainage of aqueous
- Under drainage of aqueous
- Blood in A.C
- Passage of aqueous through unintended channels.
- Cataract

c) BUPHTHALMOS(ox-eye).

- Caused by mainly congenital maldevelopment of trabecular meshwork (canal of schlemm) hence drainage system is poor. It may present with blockage or absence of canal of schlem, or AC abnormalities.

Clinical features

- Infant presents with large blue/grey eyes (cornea is overstretched by pressure)
- Photophobia
- Is usually bilateral
- cornea big (megalocornea) looks like ox eye (normal size 10-11mm)
- deep cupping of the optic disc
- pressure 25-45mmHg
- irritability
- lacrimation

Diagnosis

- Proper examination of the eye
- patient is taken to theatre for EUA.

Management

- Surgery is done.
- Geniotomy is done- Geniotomy knife is used to sweep over the angle of the eye, and try to open the channels.
- Trabeculectomy may also be done.

Post op care

- Eye dressing (aseptic technique);eye antibiotics/drops.
- Ct checking the depth of anterior chamber.

Complications

- Corneal or scleral perforation.
- Exposure keratitis due to poor lid closure.

Prevention

- Early diagnosis and treatment of the eye condition.
- Health education.

d) Secondary glaucoma

- It occurs secondary to other conditions of the eye or the body.e.g:
- Lens-(lens dislocation, cataract).
- Uveal tract conditions(iris choroid and ciliary body)
- Trauma-(AC to collapse, laceration of the cornea)
- Systemic condition e.g. DM, thyroid dxs.
- Prolonged use of steroids.
- Tumors of the eye.
- Post-operatively (edema, flat anterior chamber)
- River blindness.

Management

- As per stages like other types of glaucoma.
- Diamox and pilocarpine may be prescribed
- Follow up closely in clinic as surgery may be necessary.

6. TRACHOMA

- It is a chronic type of conjunctivitis, soon affecting the cornea. it affects the inferior and superior tarsal conjunctiva.
- It is caused by ***C.trichomatis***.
- Incubation 5-14 days
- Acute in adults.
- Associated with low socio-economic status and poor hygienic conditions.
- It is common during dry weather and dusty atmosphere.

Mode of transmission(4F'S)

- Person to person e.g. sharing a towel
- Self contamination
- Contaminated water, fingers
- Poor personal hygiene
- Latrine uncleanliness
- Transmitted by the big blue house fly (toilet)

Clinical features

- red eyes (hyperaemia of conjunctiva)
- Discharge/ lacrimation.
- Itching with burning sensation.
- Pannus (blood vessels grow towards cornea)
- Poor vision
- Photophobia
- Pain

WHO CLASSIFICATION OF TRACHOMA

i. T. Inflammation folliclular-more than 5 follicles (trachomatous)
ii. T. inflammation intense- signs of inflammation e.g. redness, pain ,swelling etc
iii. Trachomatous scarring-no inflammation, trachoma healed but scars present.
iv. T.trichiasis-inturn of eye lashes (complication)
v. Corneal opacity-eye lashes have scratched the cornea, healed and scars and the patient can't see.

Management

- Topical antibiotics.-T.E.O 3% both eye tds for 6 wks, each time after cleaning the eye with warm n/s.
- Systemic antibiotics e.g. oral tetracycline 500mg tds for 7-10 days.
- Expectant mothers/babies less than 7 yrs given erythromycin.
- Oral azithromycin 1gm STAT may be given.
- Encourage face washing and good nutrition.
- Community treating 1% T.E.O.BD for 5 days every month to control spread .

Surgical Management

- Epilation.
- Tarsal plate rotation(TPR)-shortening of upper eyelid.
- Electrolysis-to burn eye lashes from the follicle to inhibit growth
- Cryotherapy-use of ice to inhibit growth.

Complications

- Blockage of tear glands thus reducing pxn of tears
- Repeated infection.
- Corneal scaring/corneal ulcer.
- Trichiasis

Prevention

- Improve standards of living.
- Availability and proper use of latrines
- Health education on personal hygiene and community hygiene.
- Accessibility to health facility
- Availability of clean water to all.
- S-surgical in keratinoplasty
- A-antibiotic therapy e.g TEO and erythromycin.
- F-face washing
- E-education and environmental education.

POSTERIOR UVEITIS

- Inflammation of the choroid and part of the ciliary body.

Causes

- Bacteria–N.gonococci, T.pallidum.
- Viruses–herpes simplex
- Parasite– toxoplasma
- Trauma
- Chemical irritants
- Gout
- Infection of the adjacent structures

Diagnosis

- Hx from previous infection e.g. syphilis.
- Eye examination
- Microscopy examination e.g. white/grey patches, inflamed retina, swollen optic nerve, cloudy vitreous and retinal detachment, retinal haemorrhage

Management

- Steroids for short duration to suppress inflammation
- Analgesics for pain
- Antibiotics e.g. ciprofloxacin
- Antiviral e.g. acyclovir.

Complications

- Cataract
- Optic inflammation
- Retino-atrophy and degeneration of retina

Prevention

- Early treatment of systemic and other eye conditions.

ANTERIOR UVEITIS

- inflammation of the iris and ciliary body part(anterior).
- Caused by the conditions of the eye and other systemic disorders e.g ulcerative colitis ,syphilis, Dm, rheumatoid arthritis, corneal ulcer, trauma, HIV patients.

Clinical features

- redness in the eye though it may not generalized.
- Painful
- Photophobia
- Reduced visual acuity
- Iris may be swollen or nodular.
- Hypopion (pus in the anterior chamber).
- Swollen or ulcerated cornea.

Diagnosis

- Take intensive hx of the disease
- Eye examination/microscopy-slit lamb is used
- Investigate ESR. Serology, Hb, x ray r/o TB, blood sugars.

Management

- Atropine-pain relieve/pupil dilate.
- Heat application/cold compressions
- Follow up/uveitis recurs
- Antibiotic to prevent infection
- Photophobia glasses

- Steroids to reduce inflammation e.g. betamethasone, sodium phosphate

Complication

- Secondary glaucoma
- Anterior /posterior synechia
- Blockage of trabecular meshwork
- Cataract
- Hypopion

Prevention

- Early tx of eye and other systemic conditions
- Prevention of trauma

CATARACT

- Opacity of the natural crystalline lens. involves pathological changes within the lens.
- The lens is totally avascular. acquires nutrients from A.H.
- The lens is enclosed in a capsule and suspended by suspensory ligaments attached to the ciliary body.
- The function is to refract light.

Types include

- ***Traumatic cataract***–surgery (trabeculectomy).
- ***Congenital cataract***–maternal illness (measles)
- ***senile cataract***–with increasing age
- ***Secondary cataract***–sec to eye and other systemic conditions e.g. uveitis, Dm etc.

Causes

- Is usually idiopathic but associated with;
- Excessive exposure to sun rays/u.v rays
- Acute diarrhoea in childhood
- Poor nutrition
- Smoking
- Aging

Degrees of cataract

- ***Immature***–only part of capsule is opaque (looks cloudy)
- ***Mature***–becomes thick (the whole lens is opaque).
- ***Hypermature***–very thick

Clinical features

- white pupil-shine a torch/opacity of lens/cloudy.
- visual disturbances/gradual loss of sight.
- Double vision.
- No pain

Management

- Has no medical treatment.
- Surgical management-it is not an emergency
- Pre/post op care/under local anaesthesia. child or aged(old),under GA.
- NPO 4hrs b4 the operation
- Clean eye with warm normal saline and povidine iodine 2% and pad the eye
- 10mls of lignocaine ,paralyses the optic nerve.
- Types of operations done depend on the nature
- Dilate the pupil one hour before the operation.

- Investigations
  - -eye swab for c/s,
  - -urinalysis
  - -Keratinometry-curvature of the cornea
  - -Biometry-size of the lens to be used.
  - -Ultra sound-to ensure no problem at the back of the eye.

Types of operations done

- Extra capsular–the posterior part of capsule is left in position, all the inner material will be removed, and this procedure gives an allowance for fixation of an artificial lens to be held in position to the posterior part of capsule.
- Intracapsular–the whole lens is removed the suspensory ligaments are ruptured.

Post op Management

- Eye padded for 24 hrs
- Instil antibiotics, steroids and analgesics
- Examination daily/check up.
- Health education on rest, light diet, avoid lifting heavy weights and prevention of infection.
- From theatre, sleep in prone position on the operated side to prevent oedema/ hyphema.
- Drug compliance
- Prevent stress on the suture line.
- Follow up to 2wks post op

Complications

- Vitreous/aqueous loss
- Increase pressure of the eye
- Retinal detachment
- Hypopyon
- Uveitis

Prevention

- Senile is unpreventable
- Others is by avoiding the predisposing causes
- Avoid long use of steroids
- Early treatment of eye conditions
- Frequent eye check up esp. Dm pts.
- Avoid smoking
- Avoid unnecessary use of cosmetics/shampoo etc

CONDITIONS OF THE RETINA

a) Retinitis
b) Retinoblastoma
c) Retinal detachtchment.

a) RETINITIS

- Inflammation of the retina
- There are two types :

I. cmv retinitis.
II. Retinitis pigmentosa

i) Cytomegalovirus retinitis

- Its caused by cytomegalovirus. Opportunistic infection in the HIV patients

Clinical features

- Pain/blurred vision
- Floaters
- Retinol exudates
- Retinol haemorrhages
- Optic disc necrosed/ appear white.

MANAGEMENT

- Examination and history taking
- Investigations: FHG, sero, ophthalmoscopy, photography
- Counselling- condition is reversible/refer if you can't counsel
- Acyclovir antiviral drug- gancyclovir 5mg/Kg bwt b.d 3wks or single dose daily or P.O 3g daily. Ganciclovir also given to decrease viral load.

ii) Retinitis pigmentosa

- retinol degeneration and its hereditary
- The patient will complain of night blindness(destroyed rods) either peripheral/central vision
- Depends on the site, patient complains of tunnel vision(tube)
- on exam, retina is black –dead cells

Diagnosis

- History-other persons in the family may have the condition.
- Narrowed blood vessels-retina dead

Non specific management

- Genetic counselling- probability of giving birth to such children

Complication

- blindness

b) RETINO-DETATCHMENT

- Separation of the epithelial layer from the neural layer of the retina due to a potential space called ***sub-retinal space***.
- It can result due to inflammation

Causes

- Traction (pull off) either as a result of fibrosis/ healing by scarring.
- A lesion or tumour being the retina that pushes forward the retina leading to the detachment. Products of inflammation may block the space
- Trauma causes a hole at the retina and can expand

Clinical manifestation:

- Photophobia
- Loss of visual bit
- Painless

Diagnosis

- Exam- a hole, tear, exudates, pigments, blood vessel dark.

MANAGEMENT

- Complete bed rest 10-14 days.
- Pad both eye, instil mydiatrics
- Sedate the patient
- Counselling and support
- Offer health education

PRINCIPLES OF MANAGEMENT

- Space to reduce so that retina remains intact.
- Seal the /tear- leser therapy or surgery, encircling -rubber band tied
- Vitrecretomy- Drain the fluids, exudates etc.replace the space with gas, bubble may be replaced .

post operation

- Pupil remain dilated for sometime
- Nurse the patient in dependent position
- Bedrest

COMPLICATION

- Ischemia
- Cataract
- Bubble expanding- uncomfortable
- Glaucoma
- Other social and psychological complications.

C) RETINOBLASTOMA

- It is the commonest malignant (primary) intra-ocular tumour in childhood. it follows proliferation of neural cells that fail to form normally in luteal. normally is detected at 18 months of age. clinically is apparent at 3 years
- Its hereditary and can either grow inwards or outwards.
- It's a fatal condition and the prognosis is very poor
- Incidence is 30% unilateral or bilateral

Clinical features

- a white pupil clearer in dim light, at night (cat eye)
- may also have a squint(adaptation to survive)
- intraocular inflammation (pain present)
- secondary glaucoma may set in
- eye protrusion (proptosis) coz of pressure.
- Redness
- hypopion

Diagnosis

- Take hx r/o a member of family with that condition in childhood, any medication during pregnancy.
- General examination under GA in theatre(examine both eyes)

Management

- Enucleation of operation eye contents and parts of optic nerve are removed(sclera is removed and sutured)
- Prepare the patient for theatre under GA
- Monitor weight and diet for sometime before the theatre
- Cytotoxic/analgesic drugs(2wks) to reduce tumour/painful drops during instillation
- Radiotherapy to reduce the tumour
- Alot of fluid in diet and food rich in iron, milk etc
- After operation prosthesis will be inserted
- Obtain consent from the parent/guardian.

- Investigation-FHG, GXM, blood sugars, BS.

Post op

- Check the site for bleeding
- In recovery position
- Analgesics/antibiotics
- Remove the pressure bandage after the 1st day
- Clean & examine the eye. instil 1%TEO
- Teach the mother to remove prosthesis, clean the socket and replace the prosthesis.
- Follow up care/recognize signs of infection, biopsy report
- Community therapy

Complication

- Metastasis
- Blindness/brain ca
- Liver ca
- Glaucoma

REFRACTIVE DISORDERS

- Are optical defects of the eye that prevent light from being brought to sharp focus by the cornea /lens on the retina
- Rated under visual acuity
- Normal eye (Emmetropia)
- If the eye with refractive error (ametropia)

MYOPIA

- Light rays are focused in front of the eye; short sightedness.
- It may be due to a too long eyeball or curvature problem.
- Lens/cataract, thicker than normal
- Kerato connus- cornea is over curved outwards

Clinical feature

- Can not see far things and can only see near objects
- Headache

Management

- Refraction and correction
- Concave spherical lens

HYPEROPIA

- Long sightedness patient say to see far objects but cannot see near. Due to too short eye ball,
- Patient may present with sideways headache
- Management is by refraction and correction use convex spherical lenses

PRESBYOPIA

- Occurs due to age usually > 40years.as people age.
- Distant vision not affected but near vision is affected.
- The lenses are unable to contract and refract light due to aging (the natural crystalline lens loses its elasticity) –accommodation
- Loss of elasticity of the lens–corrected by the convex lenses–plus

ASTIGMATISM

- Curve of the cornea is uneven- not smooth
- Non-spherical cornea and looks like an egg and images are focused at different focuses on the retina
- Patient reports to seeing different things on what is actual
- Correct using cylindrical lenses
- Mostly it may accompany myopia or hyperopia.

APHAKIA

- Its the absence of the lens either congenital/other
- Intraocular artificial lens may be put on correction
- Corrected by a very high convex spherical lens

PSEUDOPHAKIA

- The presence of artificial lens instead of the normal crystalline lens.
- May have a higher refractive power than the normal eye.

EYE IRRIGATION

- Its eye washout

Indications:

- Excessive eye discharge
- Chemical reactions/burns

procedure:

- Lignocaine drops to decrease sensitivity/pain
- Normal saline warm drip move it from all the sides of the eye.
- Don't irrigate the cornea directly to avoid trauma, the patient move the eye all around so as to wash mideal / lateral cauthus
- Litmus paper to test the PH of the eye-the degree of alkalinity/acidity
- Irrigate until PH 7.4 and below
- Nasal of the drip and the eye should be 2 inches away.

TRAUMA

- First Aid- perforation, penetrating, lid trauma- depends on the site.
- For penetrating -pad and refer the patient/shield
- Give oral antibiotics, analgesics
- Blunt trauma-oral antibiotics/ analgesics T.T 0.5mls stat as per schedule
- Refer the patient
- Education on prevention of trauma

CONGENITAL OCULA ABNORMALITIES

- Developmental anomalies-developmental causes, infections TORCH, drugs used by the mother in pregnancy.
- Eyelid-ptosis-dropping of the upper eyelid
- Cornea- kerato connus, megalocornea
- Iris-iris coloboma, aniridia, albinism-lack of melanin
- Heterochromia-more than one colour of the iris
- Misplaced pupil, more than one pupil

- Lens- congenital cataract, aphakia
- Anterior chamber- absence of the canal of Schlem, blocked.
- Choroid/retina coloboma – congenital tumour e.g. retinoblastoma,
- no eyeball, too small –micro eye, more than two eye balls.

BLINDNESS

A condition of lacking visual perception due to physiological or neurological factors.

Many forms exist including colour, light, image, movement and acuity.

May affect one or both eyes.

Total blindness –complete lack of visual light perception,clinically recorded as “NLP”no light perception.

keratitis

retinoblastoma

olves gradually within 10 to 14

n or infection of the conjunc-
s results from exposure to al-
ntagious. Infectious conjunc-
erial or viral infection and is
o person.

NAGEMENT

ivitis include conjunctival
scular injection (engorge-
ot" appearance), excessive

on of vasoconstrictors and
is instructed to avoid using
unctivitis subside.
pink eye," is caused by
us influenzae, or *Pseudo-*
ude blood vessel dilation,
and discharge. The dis-
adually becomes thicker

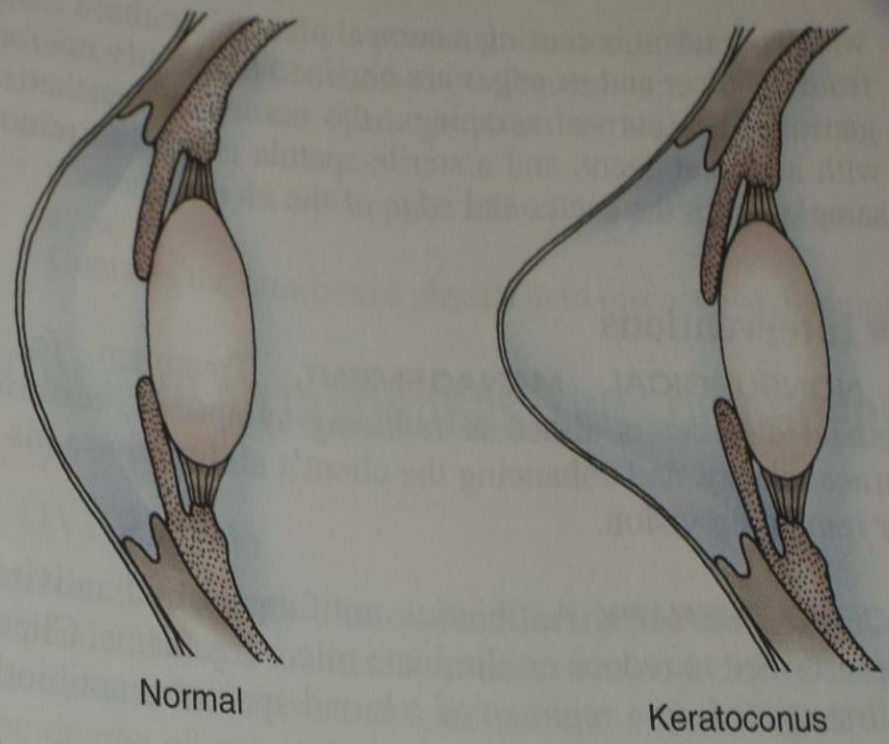

Figure 47-4 • Profiles of a normal eyeball and one with keratoconus.

TABLE 47-1 • COMMON CAUSES OF CORNEAL DISORDERS

KERATOCONUS	KERATITIS (*ACANTHAMOEBA*)
• Autosomal recessive trait • Down syndrome • Aniridia • Marfan syndrome	• Protozoal infection

sensory retina, allowing some
reous to seep through the sensory retina a
m the RPE (Fig. 58-11). People at risk for th
ment include those with high myopia or ap
act surgery. Trauma may also play a role in
us retinal detachment. Between 5% and 1

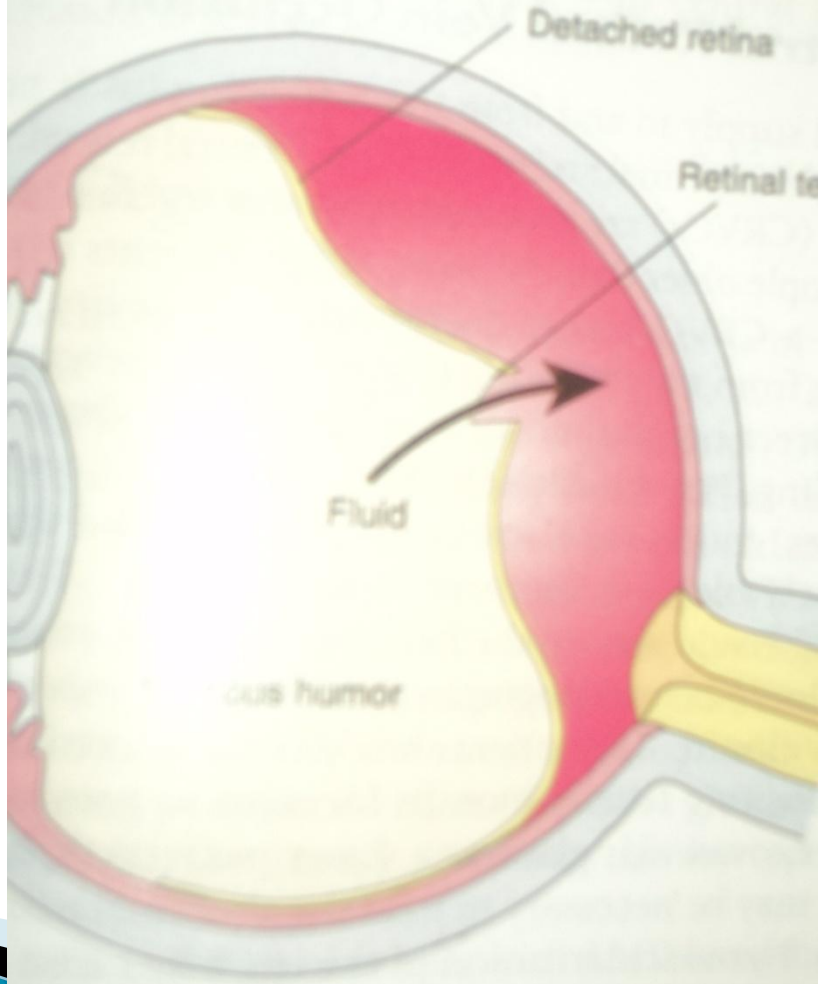

FIGURE 58-11 Retinal detachment.

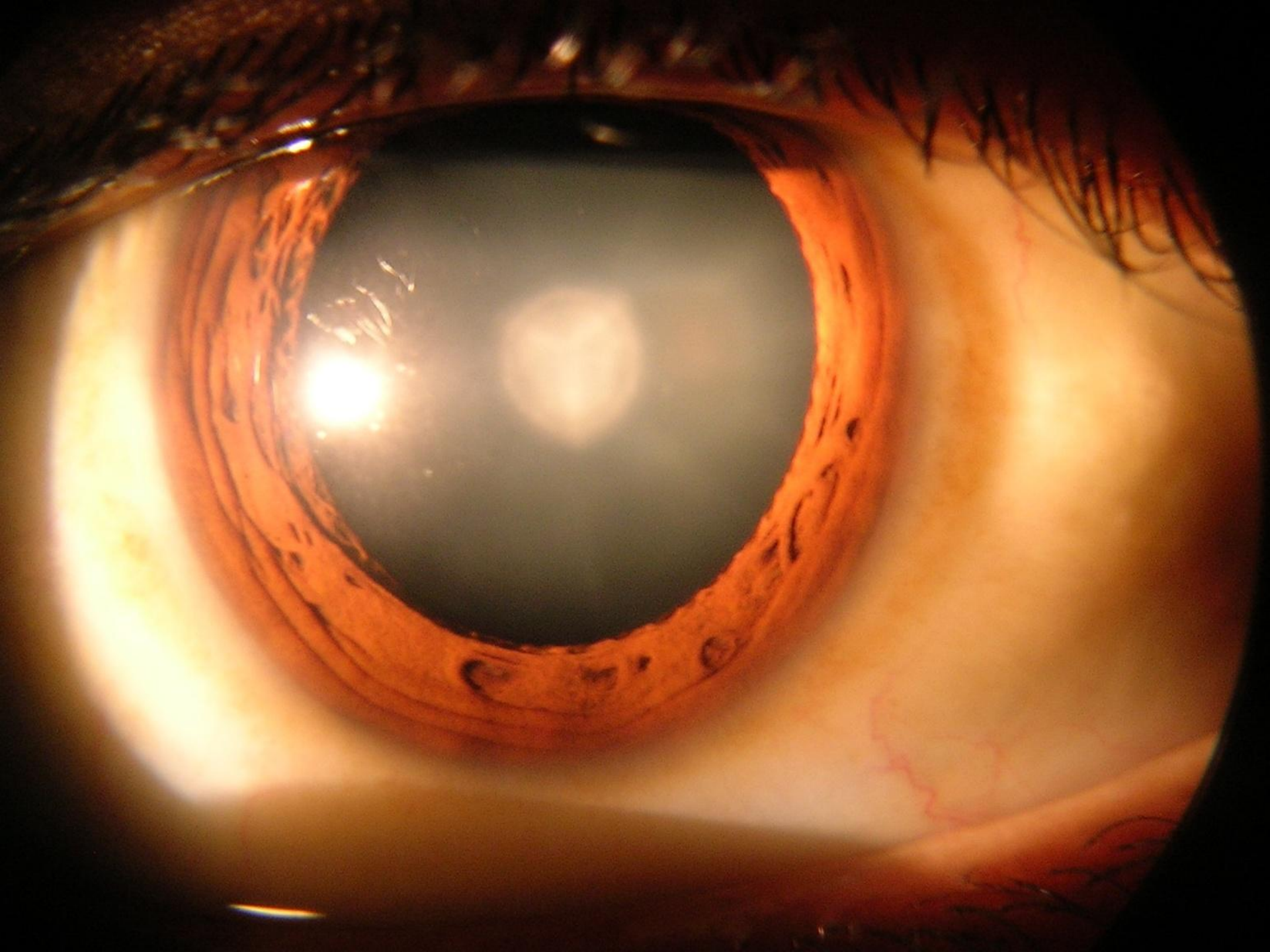

enjoypic.com

What Next